

## CASE REPORT

### **Role of Partial Hydrolysed Guar Gum in Chemotherapy Induced High Output Stoma in Patient with Ileostomy**

Ho Chiou Yi<sup>1,3</sup>, Atiki Falparado Ahmad<sup>2,3</sup>, Woo Sze Sian<sup>2,3</sup>, Tharmasilen A/L Selvarajoo<sup>2,3</sup>,  
Norshariza Jamhuri<sup>1,3</sup>, Zuliehaiza Kahairudin<sup>1,3</sup>

<sup>1</sup>Department of Dietetic and Food Service, National Cancer Institute, Ministry of Health, Malaysia

<sup>2</sup>Department of Surgical Oncology, National Cancer Institute, Ministry of Health, Malaysia

<sup>3</sup>Nutritional Therapy Team, National Cancer Institute, Ministry of Health, Malaysia

#### **ABSTRACT**

**Introduction:** High and excessive stoma output from ileostomy, is frequently observed in patients with ileostomy under radiation and chemotherapy thus deteriorate illness. As part of treatment, partially hydrolysed guar gum (PHGG) was used to resolve the problems effectively. **Case presentation:** An Indian male age 68, Mr S, with no underlying illnesses, diagnosed with rectal and prostate adenocarcinoma underwent laparoscopic anterior resection with covering ileostomy, followed by three month chemotherapy. After second cycle of chemotherapy, he developed persistent high stoma output (>2litres/day) leads to lethargy due to dehydration leads to the cessation. As parenteral nutrition and semi elemental diet does not benefit the patient, instead standard Oral Nutrition Supplement (ONS) with added PHGG and high protein high calories low residue diet was initiated concurrent with anti-motility and anti-secretory medications. Subsequently, stoma output reduced and soft in consistency and patient able to resume treatment. **Discussion:** Chemotherapy induced high-output stoma, a common problem in cancer patients, not only directly impact on patient's nutritional status but may also compromise treatment efficacy because of consequent dosing alterations or discontinuation. The obstacle that often faced with ileostomy patient is consistent high stoma output despite fluid restrictions and conservative management of stoma output with regular doses of anti-motility and anti-secretory agents, transition period to wean off TPN, promote gut adaptation and to achieve energy requirement with normal stoma output. PHGG is a water-soluble, non-gelling fibre that has provided therapeutic benefits which can provide a dichotomous features whereby normalizing effect in stool. **Conclusion:** Incorporating PHGG in feeding regime showed positive outcomes in quickly improves stoma output in patient with ileostomy as well as nutritional intake.

**Keywords:** Partially Hydrolysed Guar Gum, ileostomy

#### **INTRODUCTION**

One of complication following radiation and chemotherapy on colorectal cancer was excessive and high stoma output which frequently observed in patients, resulting in deterioration in nutritional outcome that leads towards treatment interruption. Gastrointestinal (GI) mucosal barrier within the radiation volumes with severe mucositis might cause diarrhoea, nausea, emesis

and severe malabsorption followed by infections with dehydration and electrolyte disorders<sup>1</sup>. Partially hydrolysed guar gum (PHGG) was proven to be effective in the treatment of acute diarrhoea in intensive care setting<sup>2</sup> which had been adapted into high stoma nutritional management. Purpose of this case report is to share our clinical experience about role of PHGG in chemotherapy induced high stoma output in patient with ileostomy

-----  
**Corresponding author:** Ho Chiou Yi  
Email: dtho@nci.gov.my

**CASE PRESENTATION:** A 68 year old Indian male, Mr S, with no underlying illnesses, diagnosed with a double primary of rectal adenocarcinoma Stage 3 and prostate adenocarcinoma stage 4 Gleason score of 4+3. He underwent a laparoscopic Anterior Resection with covering ileostomy and followed by chemotherapy. Post second cycle of chemotherapy, he experienced 8% weight loss within 1-month, developed persistent high stoma output and lethargy due to dehydration even withholding chemotherapy for seven days. Patient was referred to Nutritional Therapy Team (NTT) consist of surgical team, dietitian and pharmacist. Nutritional diagnosis was altered gastrointestinal function related to compromise gastrointestinal (GI) tract function due to radiotherapy as evidence by high stoma output. Initially, stoma output was more than two litres per day. Anti-motility and anti-secretory medications were prescribed with high protein high calories low residue diet plus standard oral nutrition supplement (ONS) support at first phase but stoma output remained high. Despite dosage increment in anti-motility and anti-secretory medication, nil-per-oral and initiation of Total Parenteral Nutrition (TPN) strategy during the second phase, stoma output remains unsatisfactory. Semi-elemental ONS was prescribed concurrently with partial TPN with same medications dosage then but patient not complied with semi-elemental ONS due to

unpleasant taste and stoma output did not show any improvement. Thus, standard ONS with PHGG was initiated, four times a day with modified high protein high calories low residue diet and wean off TPN were allowed with same dosage of anti-motility and anti-secretory medications. Finally, the stoma output reduced with soft consistency stools upon discharged. In addition, total daily energy and protein intake increased after started with PHGG.

## DISCUSSION

Human intestine works on approximately 8-10litres of fluid daily, most of fluid is absorbed by the jejunum and the ileum while estimated 1.5litres reaches the colon, of which 100 ml is excreted<sup>3</sup>. Most chemotherapeutic agents target rapidly dividing cells, and effects on these cells within the gastrointestinal tract can lead to a variety of symptoms. Chemotherapy treatment might induce severe mucositis and cause high-output stoma in patient with ileostomy. High-output stoma usually is considered as output greater than 1.5litres/day<sup>4</sup>. The chemotherapy-induced high-output stoma not only directly impact on patient's nutritional status but may also compromise treatment efficacy because of consequent dosing alterations or discontinuation<sup>5</sup>. High-output stoma can lead to dehydration, renal dysfunction, and electrolyte abnormalities<sup>4,6</sup>.

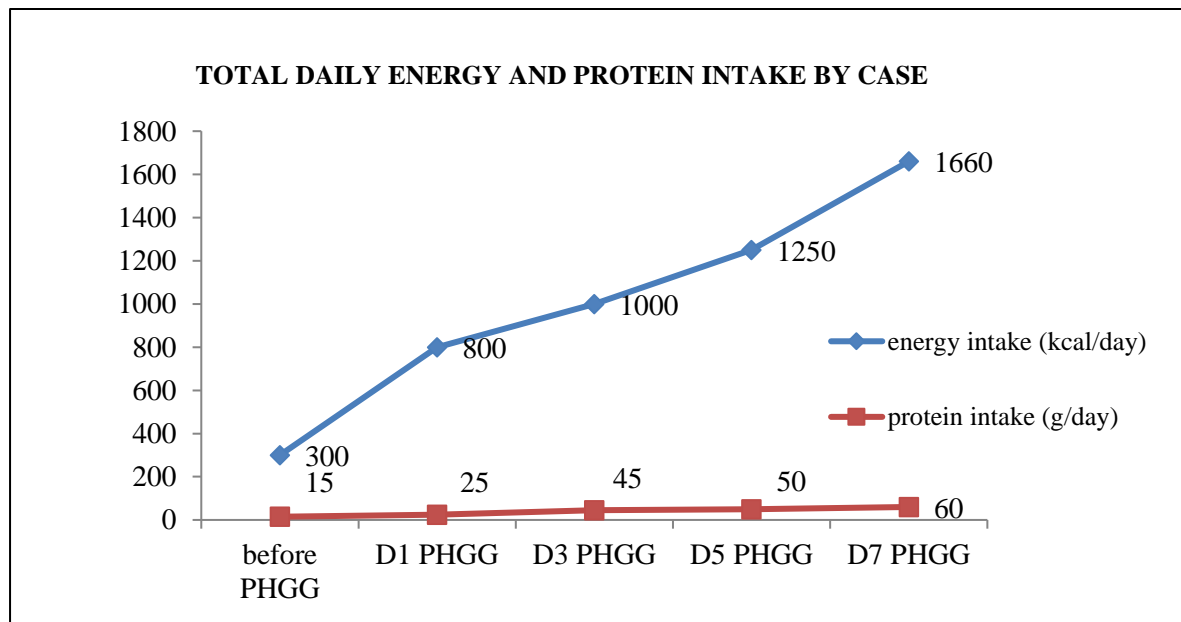


Figure 1: Total Daily Energy and Protein Intake

The presented patient was on parenteral nutritional support and reported a consistent high stoma output despite fluid restrictions and consuming glucose-saline solutions collectively with regular doses of anti-motility and anti-secretory agents. The challenge of high output stoma in ileostomy patient is to wean off TPN, promote gut adaption and achieve energy protein requirement with normal stoma output<sup>7,8</sup>. In the effort of reducing and controlling ileostomy output, patient should be educated and complied with the management. Appropriate high stoma output management includes restriction of fluids, medications, and dietary modification<sup>9</sup>. High calories high protein low residue normal diet was prescribed to compensate for malabsorption by hyperphagia. Oral Nutrition Supplement (ONS) may be necessary with insufficient intake (less than 60% from requirement) to optimise oral intake and minimize nutritional depletion<sup>10,11</sup>. However, unpleasant taste and higher cost of semi-elemental and elemental ONS might affect the long term compliance of ONS<sup>12</sup>.

Other than management as stated above, soluble fibre supplement, such as guar gum, might be considered in the intervention plan<sup>7</sup>. PHGG is a water-soluble, non-gelling fibre that has provided therapeutic benefits. In clinical trials, PHGG decreased symptoms in constipation-predominant and diarrhoea-predominant forms of IBS and decreased abdominal pain. Soluble fibre such as guar gum can provide a dichotomous feature whereby stool normalizing effect to soften hard stool (increase Biomass frequency) in constipation and firm watery stool (decrease Biomass frequency) in diarrhea<sup>9</sup>. Current case study showed consistent findings that PHGG showed positive effect in improving ileostomy consistency and output and subsequently prevent complications of high output.

### Limitation

Long-term nutritional effect of PHGG was not explained in this case report. The reduction in stoma output following the introduction of PHGG and normal diet could be a mere coincidence. As a result, findings from a case report cannot be generalized unless a cause-effect relationship from a representative population is established. Case reports aim to contribute to a change in the clinical practice. Numerous discoveries and major advancements in medicine started with a case report.

**CONCLUSION:** Optimal multidisciplinary management including nutritional management is crucial in management of high output in patient with ileostomy induced by chemotherapy and oncologic outcomes. PHGG in ileostomy nutritional management showed improvement of volume and consistency of stoma output and positive outcomes in term of nutritional intake. We hope this case report to can be used as an example of the effect of integration partially hydrolysed guar gum in nutritional management of oncologic treatment induced high output in ileostomy patients.

### Acknowledgement

We would like to thank the Director General of the Health Ministry of Malaysia for permission to publish this article.

### Conflict of interest

The authors declare no conflict of interest arising from the findings for the reported case and its management.

### REFERENCES

- 1) Grabenbauer GG, Holger G. Management of radiation and chemotherapy related acute toxicity in gastrointestinal cancer. *Best Practice & Research Clinical Gastroenterology*. 2016 Aug 1;30(4):655-64.
- 2) Rushdi TA, Pichard C, Khater YH. Control of diarrhea by fiber-enriched diet in ICU patients on enteral nutrition: a prospective randomized controlled trial. *Clinical Nutrition*. 2004 Dec 1;23(6):1344-52.
- 3) Kiela PR, Ghishan FK. Physiology of intestinal absorption and secretion. *Best practice & research Clinical gastroenterology*. 2016 Apr 1;30(2):145-59.
- 4) Villafranca JJ, López-Rodríguez C, Abilés J, Rivera R, Adán NG, Navarro PU. Protocol for the detection and nutritional management of high-output stomas. *Nutrition journal*. 2015 Dec;14(1):45.
- 5) Robertson JP, Wells CI, Vather R, Bissett IP. Effect of diversion ileostomy on the occurrence and consequences of chemotherapy-induced diarrhea. *Diseases of the Colon & Rectum*. 2016 Mar 1;59(3):194-200.
- 6) Baker ML, Williams RN, Nightingale JM. Causes and management of a high - output

- stoma. *Colorectal disease*. 2011 Feb;13(2):191-7.
- 7) Matarese LE, O'Keefe SJ, Kandil HM, Bond G, Costa G, Abu - Elmagd K. Short bowel syndrome: clinical guidelines for nutrition management. *Nutrition in clinical Practice*. 2005 Oct;20(5):493-502.
  - 8) Neelis EG, Olieman JF, Hulst JM, de Koning BA, Wijnen RM, Rings EH. Promoting intestinal adaptation by nutrition and medication. *Best Practice & Research Clinical Gastroenterology*. 2016 Apr 1;30(2):249-61.
  - 9) McRorie Jr JW, McKeown NM. Understanding the physics of functional fibers in the gastrointestinal tract: an evidence-based approach to resolving enduring misconceptions about insoluble and soluble fiber. *Journal of the Academy of Nutrition and Dietetics*. 2017 Feb 1;117(2):251-64.
  - 10) Acosta PJ, Borschel MW, Reynolds PA, Cordle CT, Duska-McEwen GO, inventors; Abbott Laboratories, assignee. Palatable elemental medical food. United States patent US 6,245,803. 2001 Jun 12.
  - 11) Pironi L, Arends J, Bozzetti F, Cuerda C, Gillanders L, Jeppesen PB, Joly F, Kelly D, Lal S, Staun M, Szczepanek K. ESPEN guidelines on chronic intestinal failure in adults. *Clinical nutrition*. 2016 Apr 1;35(2):247-307.
  - 12) Sica J, Burch J. Management of intestinal failure and high-output stomas. *British journal of nursing*. 2007 Jul 12;16(13):772-7.