

Research Note**Investigation of Oral Lesion Outbreak among Two Boarding School Students in Thimphu**

Pratap Singh Tamang¹, Guru Prasad Dhakal¹, Gyan Prasad Bajgai¹, Vishal Chhetri²,
Laigden Dzed³, Hari Prasad Pokhrel^{4*}

¹ *Jigme Dorji Wangchuck National Referral Hospital, Thimphu, Bhutan*

² *Royal Center for Disease Control, Thimphu, Bhutan*

³ *Nutrition Program, Ministry of Health, Thimphu, Bhutan*

⁴ *Gidakom Hospital, Ministry of Health, Thimphu, Bhutan*

ABSTRACT *Background:* The objective of the study is to determine the cause of oral lesion outbreaks among boarding school students and provide proper clinical diagnosis and treatment. *Methods:* This was a retrospective descriptive study. Data was collected from the affected students during our visit to the schools. Participants were students who had reported of various oral lesions including glossitis in two schools of Thimphu district. A total of 105 students who had oral lesions and glossitis were screened and provided symptomatic treatment. Around 20 students who had severe lesions were sent for blood investigation inclusive of C-reactive protein and micronutrient assays for serum iron, ferritin, folate and cobalamin. Oral swabs were collected and cultured to rule out any fungal growth. All the students were treated symptomatically with B-Complex multi-vitamin, analgesics and with amoxicillin in suspected bacterial super imposed infection. The students were followed up after 2 weeks and 4 weeks of the first visit. *Results:* Over two-third (70%) of the severely affected students were female and all blood investigation parameters were normal except for one student who had serum micro-nutrients level below the normal range. Microbial culture of oral swab did not isolate any pathogenic organism. All students reported improvement during the first visit and most students had recovered during the second visit with symptomatic treatment. *Conclusion:* All students reported improvement during the first visit and most students had recovered during the second visit with B-Complex multi-vitamin supplementation. Although the investigation was inconclusive, it strongly points towards riboflavin deficiency which is supported by glossitis outbreak investigation literature from various settings. The investigation recommends conducting a prospective study taking account of all the important micro-nutrients to establish the exact cause of deficiency.

Keywords: Oral lesions, glossitis, schools, students

INTRODUCTION

Oral health is an integral part of general health. It does not pose a major mortality threat but it substantially influences the general health and well-being of an individual (1). Mouth is the only gateway to the body and everything we eat or drink has to pass through it (2). Oral diseases are highly influenced by individual's belief, attitude, knowledge, skills, dietary habits, nutritional status, environment and day to day living practices (3). Oral hygiene is not perceived as an important procedure in most parts of the world including Bhutan and it is made worse by the inability to carry out normal daily procedures such as performing proper oral hygiene practices like tooth brushing or cleaning teeth and tongue due to various oral lesions and glossitis (4).

Oral lesions can be anything in the mouth that is not normal, an ulcer or breach on the mucosa etc. Glossitis is inflammation of the tongue generally characterized by redness and swelling. There are two major types; Benign Migratory Glossitis (BMG) and Atrophic Glossitis (AG) (5, 6). BMG or erythema migrans is an inflammatory condition characterized by focal areas of depapillation of filiform papilla. It is usually surrounded by an area of erythema or hyperkeratosis, resulting in a "map-like" appearance

on the dorsal surface of the tongue most commonly which keeps changing in its color, size and position (5, 6). BMG has variable presentation and is asymptomatic in most cases. Very rarely it is associated with systemic diseases and psoriasis (7). Atrophic glossitis (AG) is characterized by the partial or complete absence of filiform papillae on the dorsum of the tongue. It is caused by nutritional deficiencies for a prolonged duration like riboflavin, niacin, pyridoxine, vitamin B12, folic acid, iron, zinc, and vitamin E. *Helicobacter pylori* (H. Pylori) infection, fungal infections, dry mouth and other metabolic diseases can also cause atrophic glossitis (8-11). Studies have also reported the association of glossitis as heredity, allergy, hormonal factors, and smoking and in association with syndromic diseases (7, 11, 12).

In the present study, students of two boarding schools in Thimphu district of Bhutan had been suffering from different types of oral lesions and glossitis for some time. Interestingly, lesions occurred within a few months after they come to school (April-May and September-October every year). This has been happening for past 2 years and got more severe in 2019 with some students requiring treatment and even hospitalization. Reports from school authorities and Ministry of Education indicate that it affected

*Corresponding author: hari88pokhrel@gmail.com

only boarding students and they improved during school vacations (13, 14). Over the years, it has become a concern for both the Health and Education Ministries (15). However, there is limited knowledge on the topic in the country. This study aimed to determine the cause of oral lesion outbreaks among boarding school students and provide proper clinical diagnosis and treatment.

METHODS

This is a retrospective descriptive study. Data were collected from the students during visit to the schools. Participants were students who reported of various oral lesions including glossitis in two schools of Thimphu district in Bhutan. A total of 105 students who complained of different oral lesions and glossitis in these two schools were screened by Oral Medicine Specialist. Twenty students presenting with severe oral lesions were sent for various blood tests inclusive of C-reactive protein (CRP), and micronutrient assays for serum iron, ferritin, folate and cobalamin. Oral swab samples were collected and cultured to rule out any fungal growth. All the students were treated symptomatically with vitamin B- Complex multi-vitamin, analgesics and with amoxicillin in suspected

bacterial super imposed infection. The students were followed up after 2 weeks and 4 weeks of the first visit. Ethical clearance was granted by the Research Ethics Board of Health (REBH), Ministry of Health, Bhutan.

Data Management and Analysis

Data collected was double entered and validated using Epi- Data version 3.1 and analyzed using Microsoft Excel. The characteristics of the participants are presented as frequencies, percent, mean and standard deviation (SD).

RESULTS

The mean age of students was 15.8 years (SD: 1.8) and 70% of the severely affected students were female. Microbial culture of oral swab did not isolate any pathogenic organism (Table 1).

Blood investigation findings are being presented in table 2. All the parameters were normal except for one female student who had serum micro-nutrients level below the normal range (Ferritin; 8.9 and Iron 8.6). All students (100%) reported improvement during the first visit while most (88.6%) of the students had recovered during the second visit with symptomatic treatment (Figure 1) which indicates that the outbreak was caused by micro-nutrient deficiency.

Table 1: Descriptive (n=20)

Variables	Category	Frequency	Percent
Age	≤ 15	11	55
	≥ 16	9	45
	Mean: 15.8, SD: 1.8, Minimum 13, Maximum 20		
Gender	Male	6	30
	Female	14	70
Oral Swab Culture: Pathogenic organism not isolated			
SD: Standard Deviation			

Table 2: Blood Serum Parameters (n=20)

Parameter	Normal Range	Mean	SD	Minimum	Maximum
CRP (mg/dl)	<0.6	0.2	0.5	0.0	2.0
B12 (pg/ml)	130-700	498.8	218.3	246.5	988.4
Folate (ng/ml)	5.0-20	16.3	4.7	11.3	20.0
Ferritin (ng/ml)	F:13-150; M 30-400	40.9	26.8	8.9	107.3
Iron (mg/dl)	F:39-149; M:40-168	93.0	45.3	8.6	212.9

CRP: C-reactive protein, SD: Standard Deviation, F: Female, M: Male

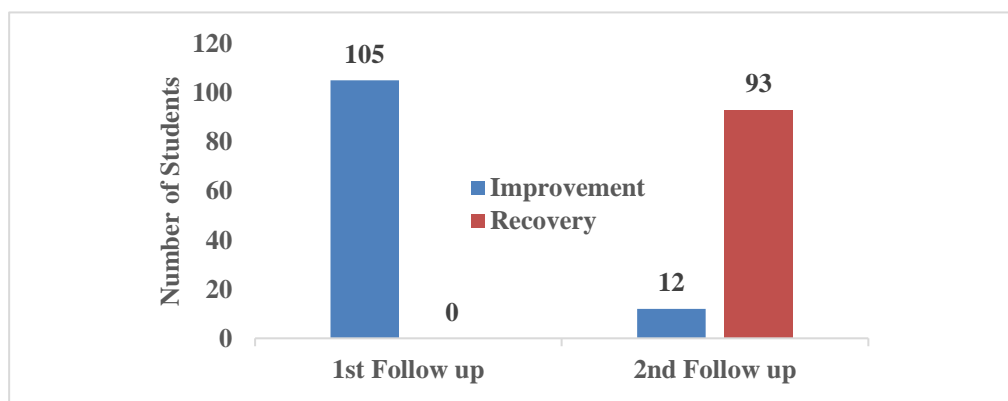


Figure 1: Improvement and recovery during follow up visits (n=105)

DISCUSSION

Students responding to B-Complex multi-vitamin supplementation indicates that the outbreaks could possibly be linked to micro-nutrient deficiencies. Past studies conducted in boarding schools have reported that that over 90% of the boarding school students were deficient in thiamine (16) and around 64% had deficiency of cobalamin (17). An investigation of meals provided in feeding schools across Bhutan found that meals had inadequate amount of proteins and micro-nutrients (18).

To address the huge burden of micronutrient deficiencies, fortified rice was introduced in feeding schools towards end of 2017. The rice was fortified with eight micronutrients (Vitamin A, vitamin B1, B3, B6, B9 and B12, iron and zinc) (19). Since the oral lesion / glossitis symptoms improved/reduced with Vitamin B complex supplementation, vitamin B2 (riboflavin) was suspected as the most likely cause of outbreaks as fortified rice lacked riboflavin but is present in vitamin B complex. Glossitis outbreak investigations conducted in different countries indicated that the outbreaks could be linked to riboflavin deficiency (20-22) Riboflavin deficiency is associated with glossitis, oral ulceration, hyperemia and swelling of mouth and throat, angular stomatitis and cheilitis. The main sources of riboflavin are meat and dairy products. Smaller amounts are also present in different cereals, food grains, seeds and green leafy vegetables (23).

LIMITATIONS

Due to urgency of the work, the investigation could not wait for resource mobilization thus, small sample size was a big limitation. The investigation also could not conduct serum assays of important micro-nutrients such as thiamine and riboflavin.

CONCLUSION

All students reported improvement during the first visit and most students had recovered during the second visit with B-Complex multi-vitamin supplementation. Although the investigation was inconclusive, it strongly points towards riboflavin deficiency which is supported by glossitis outbreak investigation literature from various settings. The investigation recommends conducting a prospective study taking account of all the important micro-nutrients to establish the exact cause of deficiency.

REFERENCES

- 1) Srivastava R, Nongkynrih B, Mathur V, Goswami A, Gupta S. High burden of dental caries in geriatric population of India: A systematic review. *Indian Journal of Public Health*. 2012;56(2):129-32.
- 2) World Health Organization. (2019). Integrated care for older people (ICOPE): guidance for person-centred assessment and pathways in primary care. World Health Organization. <https://apps.who.int/iris/handle/10665/326843>.
- 3) Osadolor O, Amuta H, Obi D, Ogbosor B. Oral Health Conditions among Elderly Patients Attending a Nigerian Tertiary Health Facility. *Journal of Dental & Oro-facial Research*. 2019;15(02):45-48.
- 4) Kelsall D, Keefe JO. Good health requires a healthy mouth: improving the oral health of Canada seniors. *Canadian Medical Association Journal*. 2014;186:893.
- 5) Stoopler ET, France K, Ojeda D, Sollecito TP. Benign Migratory Glossitis. *The Journal of Emergency Medicine*. 2018;54(1):e9-e10.
- 6) Khozimeh F, Rasti G. The Prevalence of Tongue Abnormalities Among the School Children in Borazjan, Iran. 2008;3(1).
- 7) Picciani BLS, Domingos TA, Teixeira-Souza T, Santos VdCBD, Gonzaga HFdS, Cardoso-Oliveira J, et al. Geographic tongue and psoriasis: clinical, histopathological, immunohistochemical and genetic correlation - a literature review. *An Bras Dermatol*. 2016;91(4):410-21.
- 8) Chiang CP, Chang JY, Wang YP, Wu YH, Wu YC, Sun A. Atrophic glossitis: Etiology, serum autoantibodies, anemia, hematinic deficiencies, hyperhomocysteinemia, and management. *Journal of the Formosan Medical Association*. 2020;119(4):774-80.
- 9) Cunha SF, Melo DA, Braga CB, Vannucchi H, Cunha DF. Papillary atrophy of the tongue and nutritional status of hospitalized alcoholics. *Anais brasileiros de dermatologia*. 2012;87(1): 84-9.
- 10) Erriu M, Pili FMG, Cadoni S, Garau V. Diagnosis of Lingual Atrophic Conditions: Associations with Local and Systemic Factors. A Descriptive Review. *Open Dent J*. 2016;10:619-35.
- 11) Nandini DB, Bhavana SB, Deepak BS, Ashwini R. Paediatric Geographic Tongue: A Case Report, Review and Recent Updates. *Journal of clinical and diagnostic research : JCDR*. 2016;10(2):ZE05-ZE9.
- 12) Najafi S, Gholizadeh N, Akhavan Rezayat E, Kharrazifard MJ. Treatment of Symptomatic Geographic Tongue with Triamcinolone Acetonide Alone and in Combination with Retinoic Acid: A Randomized Clinical Trial. *J Dent (Tehran)*. 2016;13(1):23-8.
- 13) Status of Students with Mouth Sores in Schools. Chhukha; 2019. Dzongkhag Education Sector, Chhukha Bhutan.
- 14) Report of Outbreak Investigation on Oral Sores (Glossitis) among the Students of Two Central Schools, Tsirang Dzongkhag, Bhutan, Sept 2018.
- 15) Executive order. MoH/DoPH/HPD/CSHP/11/2019-2020/395; 2019. Department of Public Health, Ministry of Health, Bhutan.
- 16) Dzed L, Dorji T, Pelzom D, Dhakal GP, Yangchen P, Wangmo K. Status of Thiamin deficiency in boarding school children from seven districts in Bhutan with previous history of peripheral neuropathy outbreaks: a cohort study. *Bhutan Health Journal*. 2015;1(1):49-56.
- 17) Dzed L, Pokhrel HP, Zangpo L, Pelzom D, Dendup U. Vitamin B12 Deficiency among Boarding School Children from Seven Districts of Bhutan. *International Journal of Innovative Research in Medical Science*. 2019;4(08):507 to 11.
- 18) Sherpa PL, Pokhrel HP, Dzed L, Deki K. Nutritive analysis of School Meals: An Investigation of a One-day Meal Provided in

- Feeding Schools of Bhutan. *Asian Journal of Dietetics*. 2020;2(2).)
- 19) Protocol for management of oral lesions and peripheral neuropathy. Department of Public Health, Ministry of Health, Bhutan 2020.
 - 20) Fitzgerald GH. An Outbreak of Exfoliative Glossitis in an Assam Jail. *The Indian medical gazette*. 1932;67(10):556-9.
 - 21) Sebrell WH, Butler RE. Riboflavin Deficiency in Man (Ariboflavinosis). *Public Health Reports* (1896-1970). 1939;54(48):2121-31.
 - 22) Nichols EK TL, Birungi N, McClelland A, Madraa E, Chandia AB, et al. (2013) Suspected Outbreak of Riboflavin Deficiency among Populations Reliant on Food Assistance: A Case Study of Drought-Stricken Karamoja, Uganda, 2009–2010. *PLoS ONE* 8(5): e62976. <https://doi.org/10.1371/journal.pone.0062976>.
 - 23) Malnutrition EtPHSoM. Evaluating the Public Health Significance of Micronutrient Malnutrition, 2018.