

Original**The Role of Glutamine-Arginine-HMB Supplementation
in Postoperative Wound Management in Gynecologic Cancer: Case Report**

Ho Chiou Yi^{1*}, Nur Syahida Mohamad Sharif², Loh Siew Jing², Nursyafiqah Ahmad Rosfian²,
Muhammad Amirulhafidz Mat Arifin², Nur Afifah Nabila Mohd Rusmi²,
Sabena Malini A/P Vijayakumar², Norshariza Jamhuri¹,
Mohd Norazam Mohd Abas², Jamil Omar²

¹ Department of Dietetics and Food Service, Institut Kanser Negara, 4, Jalan P7,
Presint 7, 62250 Wilayah Persekutuan Putrajaya, Ministry of Health, Malaysia

² Department of Gynaecology Oncology, Institut Kanser Negara, 4, Jalan P7, Presint
7, 62250 Wilayah Persekutuan Putrajaya, Ministry of Health, Malaysia

(received November 30, 2024)

ABSTRACT *Introduction:* Post-operative wound breakdown, is influenced by malnutrition, diabetes mellitus, and inadequate wound care. This case reports aimed to share our clinical practice regarding the glutamine-arginine- β -hydroxy β -methylbutyrate (HMB) incorporation in post-operative wound management. *Case presentation:* Patients A and B, who underwent laparotomy surgery, were readmitted due to surgical site infection and wound breakdown post-operative days 14-16 with wound score grade IV b. They experienced postoperative weight loss fortnightly, SGA B, and inadequate energy protein intake. Medical nutrition therapy (MNT) included a high-calorie high protein diet, lactose-free oral nutrition supplement (ONS), and orange-flavored glutamine-arginine-HMB supplementation. Daily dressing, antibiotics, and second suturing were done. Both patients were discharged with adequate oral intake and healed wounds on day 10 of admission. *Discussion:* Postoperative inadequate oral intake can significantly slow wound healing by causing nutritional deficiencies that impair protein synthesis, immune function, and overall energy availability. A post-operative multidisciplinary approach including a dietitian is indispensable to ensure optimal wound healing. An individualized MNT with ONS ensures sufficient intake of energy and protein while glutamine-arginine-HMB supplementation promotes wound healing by supporting immune function, collagen synthesis, antioxidant protection, and inflammation modulation. *Conclusion:* Adequate energy protein intake with proper dressing is crucial to assist efficient wound healing and lower complications. A multidisciplinary team approach, including individualized MNT with ONS and glutamine-arginine supplementation, is crucial for ensuring sufficient oral intake and promoting effective wound healing.

Keywords: Glutamine-Arginine-HMB, Postoperative, Wound Management

INTRODUCTION

Surgery is a primary treatment for gynecological cancer, aiming to remove cancerous tissues and potentially affected organs to achieve disease control and improve patient outcomes (1). Post-operative wound care is crucial to prevent infections, promote healing, and ensure optimal recovery (2). Surgical wound breakdown is influenced by various factors that hinder healing. Advanced age, malnutrition, obesity, and chronic illnesses like diabetes can compromise tissue integrity (3). Postoperative complications such as infection, excessive aggressive movement, and inadequate wound care can further contribute to dehiscence (3).

Optimal nutrition, providing the necessary minerals, protein, and energy needed, is essential for wound healing (3, 4). Immunonutrients like arginine and glutamine, as well as β -hydroxy β -methylbutyrate (HMB), enhance wound healing by supporting collagen synthesis, and immune function, and reducing inflammation (5). This case report aimed to share our clinical practice about glutamine-arginine-HMB incorporation in post-operative wound healing management.

CASE PRESENTATION

Patient A, 62 years old, diagnosed with endometrial carcinoma stage 3C and underlying

* To whom correspondence should be addressed:
agneshcy0326@gmail.com

partially controlled diabetes mellitus type II, underwent extra fascial hysterectomy, bilateral salpingo-oophorectomy and bilateral pelvic lymph nodes dissection. She was readmitted due to surgical site infection (SSI) and midline wound breakdown with the presence of minimal slough post-operative day 14. Based on the Southampton wound assessment (SWA) scale, her wound was grade IV b. Percentage of weight loss (4.7% fortnightly), SGA B (total score 15), inadequate oral intake (19kcal/kg/day and 0.7g/kg/day protein), and poorly controlled blood sugar (fasting blood sugar range at home 7-11mmol/L) was recorded. Medical nutrition therapy (MNT) included a strictly diabetic high protein diet, lactose-free diabetic oral nutrition supplement (ONS) (additional 675kcal/day and 30g/day protein), and 2 sachets of orange-flavored glutamine-arginine-HMB (1.55g HMB, 7.4g arginine and 7.4g glutamine per sachet) supplementation was implemented. Daily dressing and antibiotics were prescribed then proceed with secondary suturing before discharge. After day 10 of admission, the patient was discharged with adequate energy protein intake (30kcal/kg/day and 1.35g/kg/day protein) controlled blood sugar (blood sugar range 5-7mmol/L), and closed wound. Day 14 after discharged, her wound was improved (grade I c) during follow up visit in clinic.

extra fascial hysterectomy, left tumor debulking, right salpingo-oophorectomy, omentectomy, and left pelvic lymph nodes dissection. She had underlying pulmonary embolism and was on anticoagulant. Post-operative day 16, she was readmitted to the ward because there was undetected bleeding within the subcutaneous fat and SSI. Wound healing score of SWA was grade IV b. Percentage of weight loss (-3.6% fortnightly), SGA B (total score 12), and inadequate oral intake (21 kcal/kg/day and 1.0g/kg/day protein) were recorded. The blood has accumulated and formed a stabilised clot which slowly leaked out through the skin staplers. Because of the swelling and pain, the staplers were removed and the clots were evacuated to reduce pain and to avoid surgical site infection. MNT included a high calories high protein diet, lactose-free polymeric ONS (additional 660kcal/day and 26.3g/day protein), and 2 sachets of orange-flavored glutamine-arginine-HMB (1.55g HMB, 7.4g arginine and 7.4g glutamine per sachet) supplementation was implemented. Daily dressing and antibiotics were prescribed then proceed with secondary suturing before discharge. After day 10 of admission, the patient was discharged with adequate energy protein intake (33kcal/kg/day and 1.34g/kg/day protein) and a closed wound. Wound was improved (grade I a) during follow up visit in clinic day 14 after discharged.

Patient B, 36 years old, diagnosed with ovarian endometrioid carcinoma stage 3C, underwent an

Table 1 Southampton wound assessment (grade) of patients after MNT with glutamine-arginine-HMB supplement

	Day 0 (ward)	Day 5 (ward)	Day 10 (ward)	Day 24 (clinic)
Patient A	IV b	III c	II d	I c
Patient B	IV b	III b	II b	I a

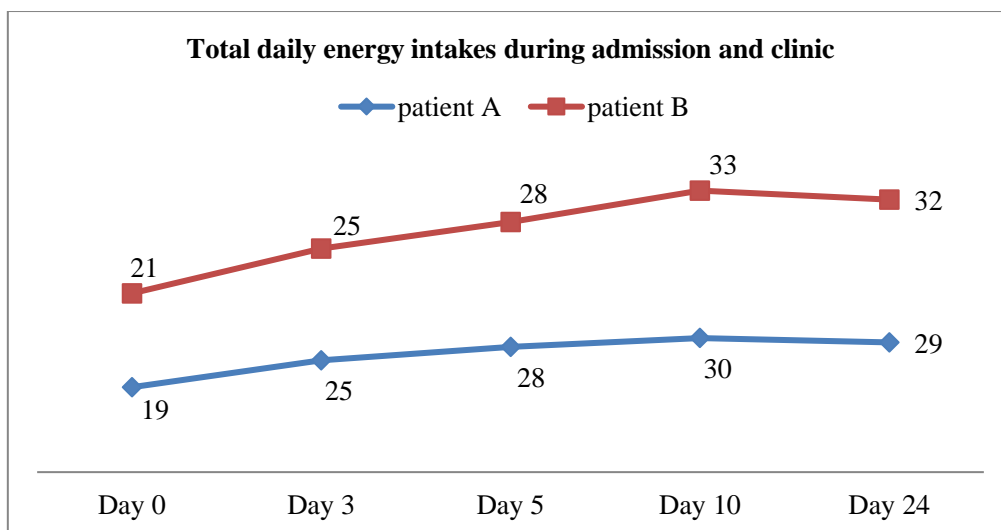


Figure 2 Total daily energy intakes during admission and clinic

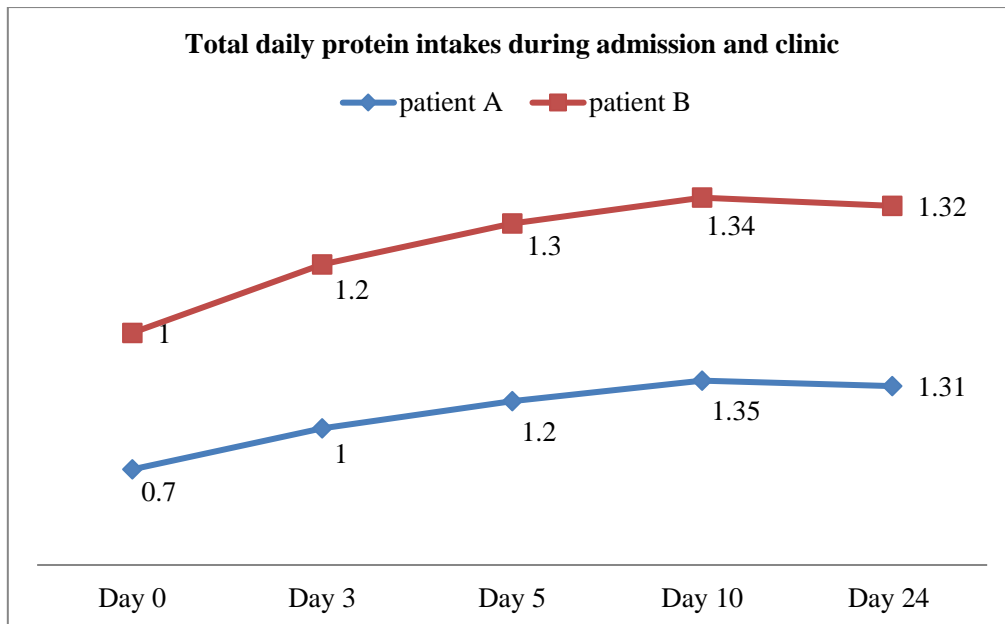


Figure 3 Total daily protein intakes during admission and clinic

DISCUSSION

Surgical wounds generally heal by primary closure during which the wound edges are brought together so that they are adjacent to each other. Wound closure is usually assisted by the use of sutures (stitches), staples, adhesive tape, or glue (6), and healing begins within hours of closure (7). Wound healing occurs in four stages, haemostasis, inflammation, proliferation and remodelling, and the appearance of the wound will change as the wound heals (8). The goal of wound management is to understand the different stages of wound healing and treat the wound accordingly (8, 9). The Southampton score was used to assess surgical wounds (10). Wounds are graded according to any complications and their extent (11). The surgical approach for SSI and wound breakdown involves assessing the wound, cleaning and debriding it, and reapproximating the wound edges using sutures, staples, or adhesive strips. Maintaining a sterile environment and providing proper postoperative care, including infection control and good nutrition, are essential for promoting healing and preventing further complications (2).

A multidisciplinary approach is indispensable in postoperative care, particularly for ensuring optimal wound healing (2, 4). Dietitians play a pivotal role in this regard, as it involves thorough assessment of nutritional requirements, regular monitoring, and the provision of personalized nutrition support tailored to each patient's needs (12). Individualized MNT with immunonutrients which are tailored to the specific needs of the patient and the type of wound are crucial for effective wound healing management (12). Nutritional support, including dietary counselling and oral nutrition supplements,

may be recommended to optimize healing outcomes and reduce complications (4). Individualized nutrition plans tailored to the patient's needs and recovery goals are essential components of post-operative care to support effective wound healing and overall recovery (12).

Optimal nutrition plays a crucial role in promoting wound healing by providing an adequate intake of minerals, protein, and energy for tissue repair and immune function (4, 13). Proteins are essential for cell regeneration and collagen formation. The production of collagen, which is necessary for wound closure and tissue repair, depends on proteins, which are the building blocks of tissues (14). Sufficient consumption of protein facilitates the wound healing process by supplying essential amino acids (15). Sustaining the higher metabolic demands linked to wound healing requires an adequate intake of energy (13). The body's ability to mend can be hampered by insufficient energy intake since it slows down tissue repair. Adequate hydration ensures proper blood flow and nutrient delivery (16). By ensuring a balanced diet rich in these nutrients, the body can effectively repair damaged tissues and reduce the risk of complications during the healing process.

Moreover, immunonutrients including glutamine, and arginine, also played an important role in wound management (17, 18). Studies showed that immunonutrients reduced postoperative wound complications (5, 17, 18). Glutamine, as a critical amino acid, provides primary energy to immunological and intestinal cells, promotes immune function by maintaining lymphocyte and macrophage activity, and aids in collagen production, which is required for wound

closure and tissue healing (19). Its antioxidant qualities shield cells from oxidative stress and boost protein synthesis, promoting tissue regeneration. Furthermore, glutamine supports intestinal barrier integrity, prevents infections, and controls inflammation to promote balanced immune responses (20). While promising, glutamine supplementation should be customized to individual patient needs, considering aspects such as health problems, nutritional state, and wound type, while adhering to clinical dosage and duration recommendations.

Arginine, an amino acid, has been shown to play a significant role in wound healing and recovery. Arginine regulates immunological responses and improves blood flow and collagen formation by acting as a precursor for nitric oxide, which promotes wound healing (21). Clinical study suggests that supplementing with arginine can enhance post-operative wound healing (17). On top of glutamine and arginine, HMB, a leucine metabolite, may aid in wound healing by increasing protein synthesis, decreasing muscle breakdown, improving immunological function, and containing anti-inflammatory effects (22). These benefits can help to enhance tissue regeneration, preserve muscle mass, prevent infections, and reduce inflammation around the wound (23).

Strengths and limitations

The current case report revealed that individualized management by dietitians is crucial to ensure adequate oral intake with ONS and glutamine-arginine-HMB supplementation to promote wound healing. This case report intends to strengthen the glutamine-arginine-HMB supplementation in MNT of wound management. The finding of the case report is hypothesis-generating. The ONS and glutamine-arginine-HMB supplement formula option was made based on routine clinical care, but this might introduce a confounding factor. More research is needed to fully understand the mechanisms and effectiveness of post-operative glutamine-arginine-HMB supplementation specifically in post-operative wound healing.

CONCLUSION

Addressing these risk factors through careful preoperative assessment, optimized surgical techniques, and diligent postoperative care is essential to prevent surgical wound breakdown. A multidisciplinary approach is crucial for postoperative management, ensuring optimal wound healing. Glutamine supplementation supports wound healing through immune function support, collagen synthesis, antioxidant protection, and modulation of inflammation, tailored to individual patient needs and clinical guidelines.

Conflict of interest

The authors declare no potential financial and non-financial conflicts of interest.

Funding source

This work did not receive any funding from public, commercial, or not-for-profit sectors.

AUTHORS' CONTRIBUTIONS

Conceptualization, methodology, formal analysis, investigation, resources, data curation, visualization, and writing original draft preparation, HCY; validation, HCY; writing – review and editing, HCY, NSMS, LSJ, NAR, MAMA, and NANMR; and supervision, NJ, MNMA, and JO. All authors read and approved the final manuscript.

ACKNOWLEDGEMENT

The authors would like to thank the nursing staff of the female surgical ward in Institut Kanser Negara, Putrajaya, Malaysia for their support in this study. The authors would like to thank the Director General of Health Malaysia for the permission to publish this paper.

REFERENCE

1. Reed N, Balega J, Barwick T, Buckley L, Burton K, Eminowicz G, et al. British Gynaecological Cancer Society (BGCS) cervical cancer guidelines: recommendations for practice. *European Journal of Obstetrics & Gynecology and Reproductive Biology*. 2021;256:433-65.
2. MacKay BJ, Dardano AN, Klapper AM, Parekh SG, Soliman MQ, Valerio IL. Multidisciplinary application of an external tissue expander device to improve patient outcomes: a critical review. *Advances in Wound Care*. 2020;9(9):525-38.
3. Gould LJ, Abadir PM, White-Chu EF. Age, frailty, and impaired wound healing. *Principles and practice of geriatric surgery*. 2020:465-82.
4. Ho CY, Ibrahim Z, Abu Zaid Z, Mat Daud ZA, Mohd Yusop NB, Mohd Abas MN, et al. Postoperative Dietary Intake Achievement: A Secondary Analysis of a Randomized Controlled Trial. *Nutrients*. 2022;14(1):222.
5. Moya P, Soriano-Irigaray L, Ramirez JM, Garcea A, Blasco O, Blanco FJ, et al. Perioperative Standard Oral Nutrition Supplements Versus Immunonutrition in Patients Undergoing Colorectal Resection in an Enhanced Recovery (ERAS) Protocol: A Multicenter Randomized Clinical Trial

- (SONVI Study). *Medicine*. 2016;95(21):e3704.
6. Coulthard P, Esposito M, Worthington HV, van der Elst M, van Waes OJ, Darcey J. Tissue adhesives for closure of surgical incisions. *Cochrane Database of Systematic Reviews*. 2010(5).
 7. Rodero MP, Khosrotehrani K. Skin wound healing modulation by macrophages. *International journal of clinical and experimental pathology*. 2010;3(7):643.
 8. Gupta A, Kumar P. Assessment of the histological state of the healing wound. *Plastic and Aesthetic Research*. 2015;2:239-42.
 9. Guo S, Dipietro LA. Factors affecting wound healing. *J Dent Res*. 2010;89(3):219-29.
 10. Bailey IS, Karran SE, Toyn K, Brough P, Ranaboldo C, Karran SJ. Community surveillance of complications after hernia surgery. *British Medical Journal*. 1992;304(6825):469-71.
 11. Campwala I, Unsell K, Gupta S. A Comparative Analysis of Surgical Wound Infection Methods: Predictive Values of the CDC, ASEPSIS, and Southampton Scoring Systems in Evaluating Breast Reconstruction Surgical Site Infections. *Plast Surg (Oakv)*. 2019;27(2):93-9.
 12. Liljeberg E, Nydahl M, Lövestam E, Andersson A. A qualitative exploration of dietitians' experiences of prescribing oral nutritional supplements to patients with malnutrition: A focus on shared tailoring and behaviour change support. *Journal of Human Nutrition and Dietetics*. 2021;34(5):858-67.
 13. Weimann A, Braga M, Carli F, Higashiguchi T, Hübner M, Klek S, et al. ESPEN guideline: Clinical nutrition in surgery. *Clinical Nutrition*. 2017;36(3):623-50.
 14. Hartwell JL, Cotton A, Rozycki G. Optimizing nutrition for the surgical patient: an evidenced based update to dispel five common myths in surgical nutrition care. *The American Surgeon*. 2018;84(6):831-5.
 15. Baron JM, Glatz M, Proksch E. Optimal support of wound healing: New Insights. *Dermatology*. 2020;236(6):593-600.
 16. Giersch GE, Charkoudian N, Stearns RL, Casa DJ. Fluid balance and hydration considerations for women: review and future directions. *Sports Medicine*. 2020;50:253-61.
 17. Chapman JS, Roddy E, Westhoff G, Simons E, Brooks R, Ueda S, et al. Post-operative enteral immunonutrition for gynecologic oncology patients undergoing laparotomy decreases wound complications. *Gynecologic Oncology*. 2015;137(3):523-8.
 18. Hertlein L, Zeder-Göß C, Fürst S, Bayer D, Trillsch F, Czogalla B, et al. Peri-operative oral immunonutrition in malnourished ovarian cancer patients assessed by the nutritional risk screening. *Archives of gynecology and obstetrics*. 2018;297:1533-8.
 19. Husain MU, Azam T, Habeeb N. Evaluating the Efficacy of L-Arginine and Glutamine on Wound Healing: A literature. *Podiatric Medical Review*. 73.
 20. Barbara G, Barbaro MR, Fuschi D, Palombo M, Falangone F, Cremon C, et al. Inflammatory and microbiota-related regulation of the intestinal epithelial barrier. *Frontiers in nutrition*. 2021;8:718356.
 21. Arribas-López E, Zand N, Ojo O, Snowden MJ, Kochhar T. The effect of amino acids on wound healing: a systematic review and meta-analysis on arginine and glutamine. *Nutrients*. 2021;13(8):2498.
 22. Prado CM, Orsso CE, Pereira SL, Atherton PJ, Deutz NE. Effects of β -hydroxy β -methylbutyrate (HMB) supplementation on muscle mass, function, and other outcomes in patients with cancer: a systematic review. *Journal of cachexia, sarcopenia and muscle*. 2022;13(3):1623-41.
 23. Kerr K, Clark R, Stampas A, Nelson J, Sulo S, Pandya D. Assessing the impact of specialized oral nutrition supplementation use on wound healing. *Archives of Physical Medicine and Rehabilitation*. 2022;103(3):e36.

